

Alcohol



Rocket City Emergency
MEDICAL CONFERENCE

**Decade 2 :
“A Bizarre Young Lady”**

**Chris White, M.D.
Nick Schoenmann, M.D.**

Decade 2: “A Bizarre Young Lady”



Chris White, M.D.

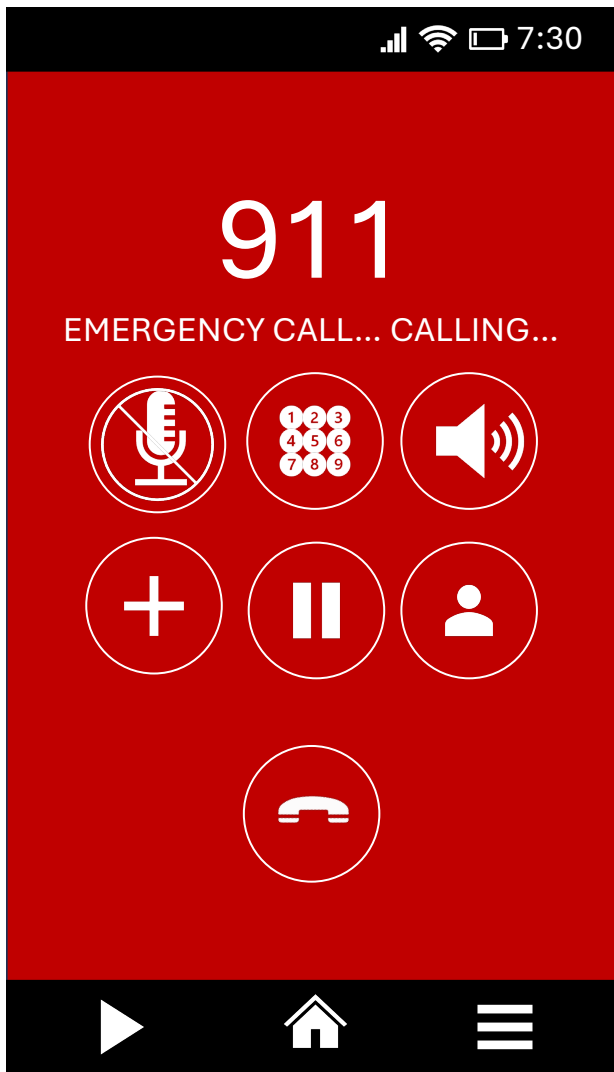

Nick Schoenmann, M.D.



Rocket City Emergency
MEDICAL CONFERENCE





EMS Dispatch

**ALS ambulance is dispatched E-3 to
“Young female acting strange at the
WAVAHO”**





Enroute

Updated to
“Possible Psych”





On Scene

Mildly agitated 22yo female
Pacing back and forth
Muttering to herself incoherently
Well dressed, but wearing
several extra layers inappropriate for
weather conditions

RR	HR	BP	SpO ₂
14	110	105/74	97%



On Scene

Per Gas Station Clerk: Reports seeing the young lady many times before but not recently

She has never acted like this before.

Believes she lives nearby with her family



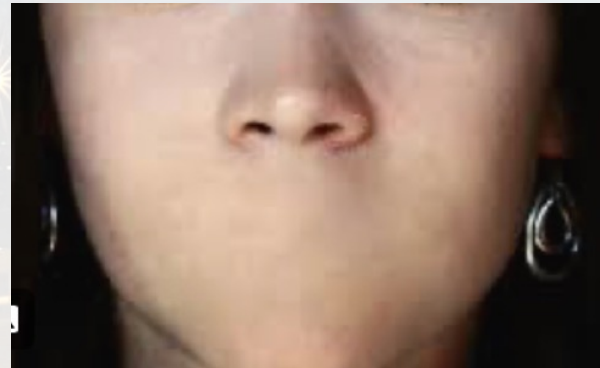

On Scene

PMHx: Unavailable; patient will not answer

Medications: Patient will not answer


Allergies: Patient will not answer





On Scene

Patient will not willingly go in ambulance



**Swings purse at EMTs,
then turns and stumbles
away**

Rocket City Emergency
MEDICAL CONFERENCE

**De-escalation
Strategies**

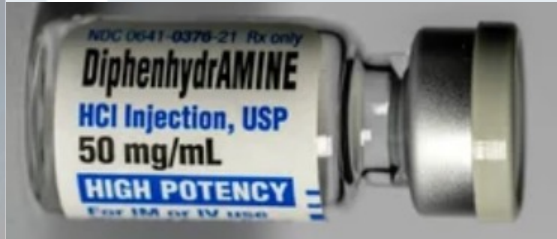


M
I
S
T



Time to medicate

Ketamine 2-4 mg/kg IM based on ideal body weight, max 400 mg



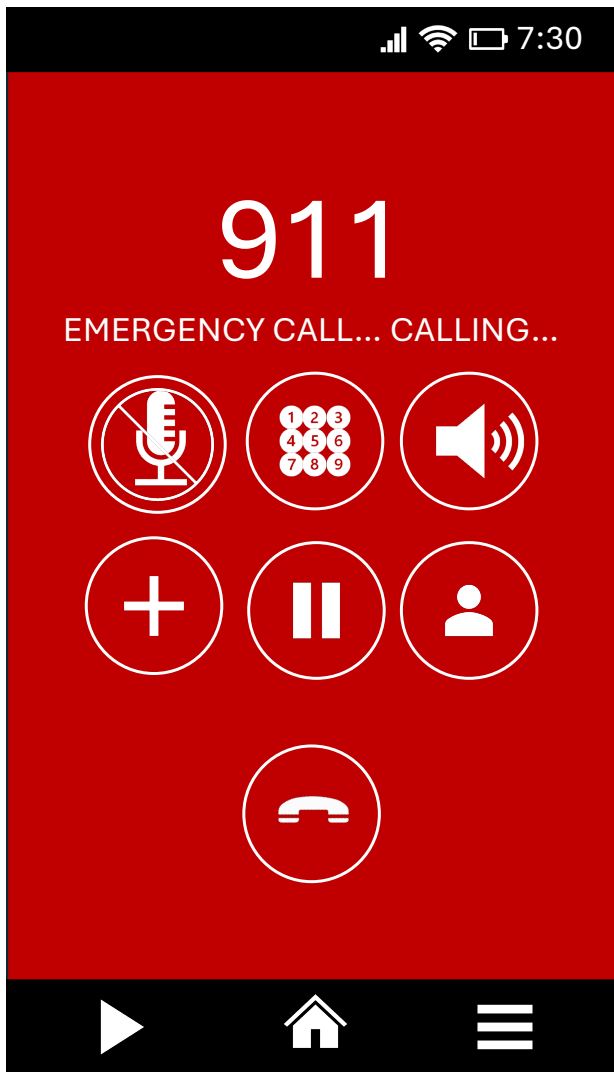Haloperidol

Haldol 0.1 mg/kg IM max of 5 mg

Diphenhydramine 1mg/kg IM max of 25 mg

EMS Transport

RR	HR	BP	SpO ₂	EtCO ₂	FSBG
22	122	134/88	99%	35mmHg	177mg%



EMS Dispatch

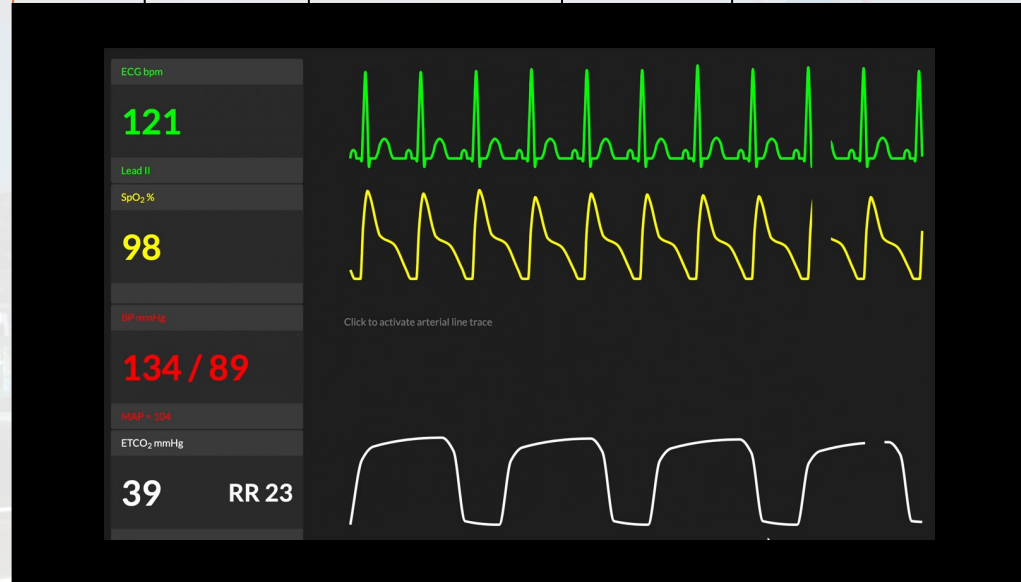**ALS ambulance is dispatched E-3 to
“Young female acting strange at the
WAVAHO”**



<https://www.flickr.com/photos/alvericemoon/>

ED Arrival

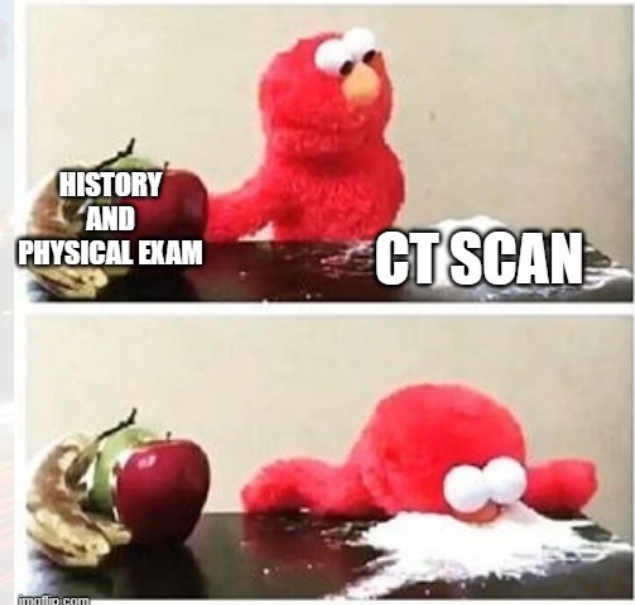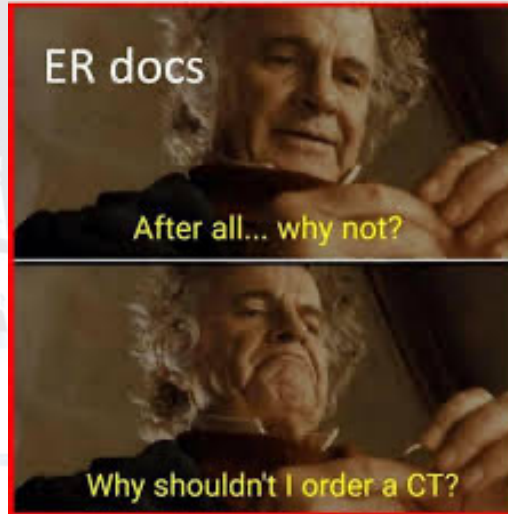
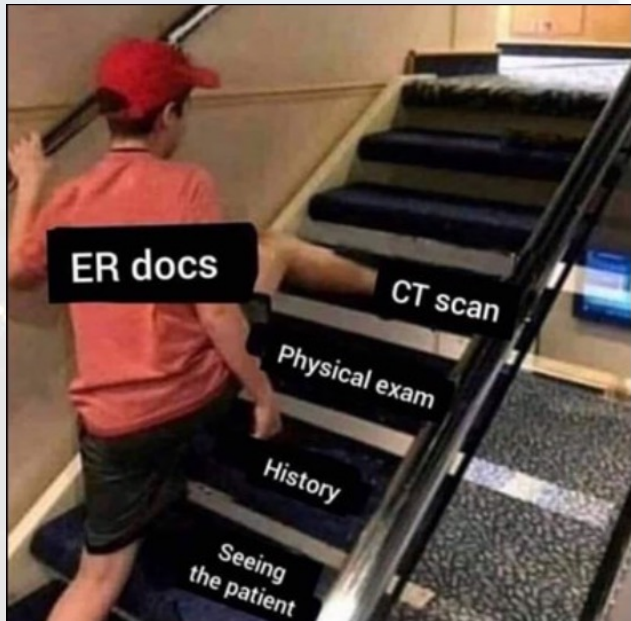
RR	HR	BP	SpO ₂	EtCO ₂
22	122	134/88	99%	35mmHg

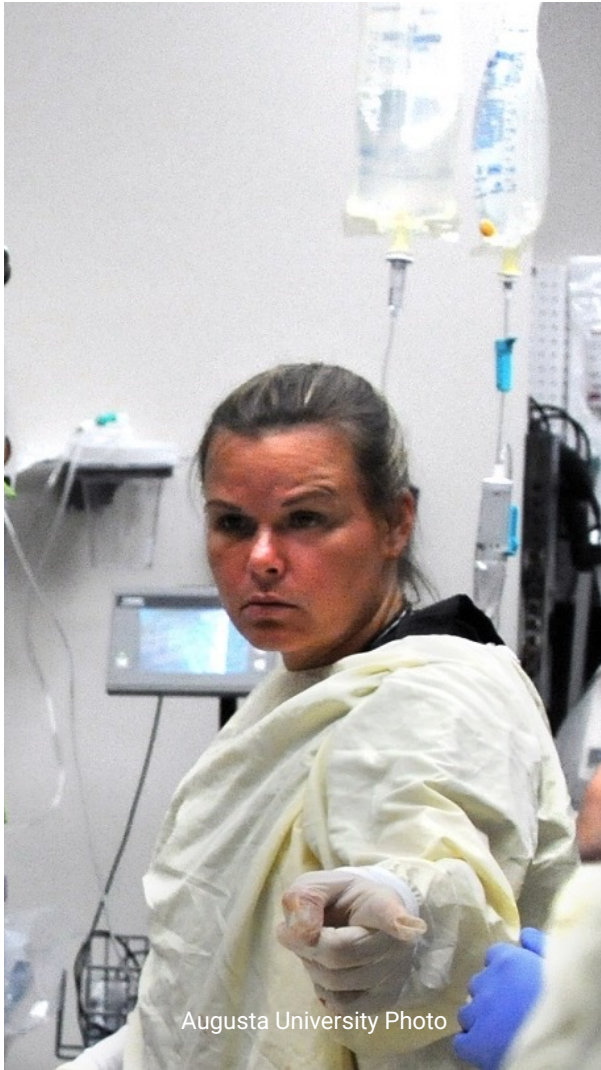

So let's summarize what we know

- We have a 22 y/o female acting strangely
- She is apparently local but never been seen acting like this before
- She is tachycardic and tachypneic
- Some mention of a psych concern

The Eval





Augusta University Photo

Reassessment

RR	HR	BP	SpO ₂	Temp
24	132	138/76	95%	39.1c

**Patient becomes more agitated,
thrashing about**



John Russell: Vanderbilt University

Reassessment

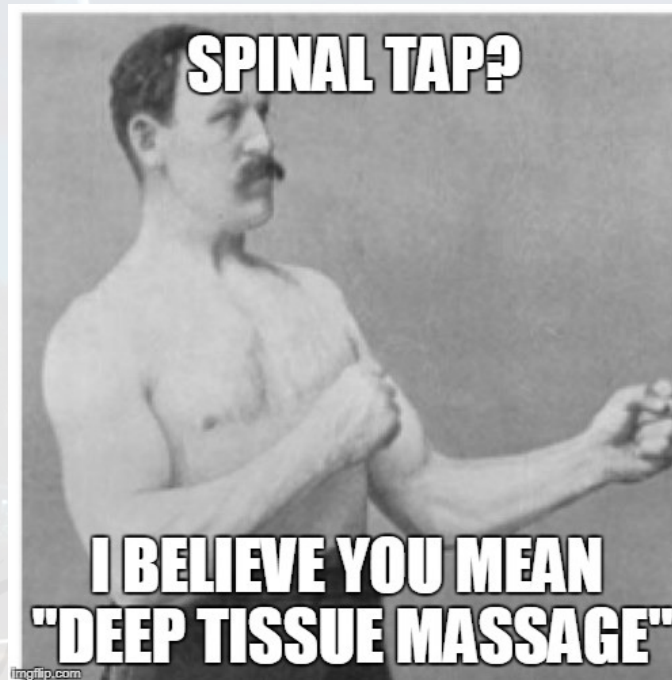
RR	HR	BP	SpO ₂	Temp
22	115	138/76	95%	38.1c

Patient is less agitated

Labs pretty unremarkable

CXR and CT Head normal

You know you gotta...



Rocket City Emergency
MEDICAL CONFERENCE



Steve Wood UAB Photo

Resolution


RR	HR	BP	SpO ₂	Temp
16	102	98/62	99%	---

Cultures/CSF pending.

The patient is admitted to step down pending completion of the workup

Following up on our patient the next day

- CSF with Anti NMDAR IgG antibodies positive
- Diagnosis: Anti-NMDA receptor encephalitis



Rocket City Emergency
MEDICAL CONFERENCE


Anti-NMDA Receptor Encephalitis

- Classical case...
- Obvious, really...



<https://pmc.ncbi.nlm.nih.gov/articles/PMC6007532/>

Panel Discussion and Q&A



**COMING
IN 2026!**

Thank you!



Altogether



Rocket City Emergency
MEDICAL CONFERENCE



COMING
IN 2026!

*A major case
of the*

BLUES

Rocket City Emergency Medicine Conference