

Altogether



Rocket City Emergency
MEDICAL CONFERENCE

**Decade 3 :
“Pregnant and Angry”**

**Stanton Royer, M.D.
Emily Kiernan, D.O.**



Decade 3: “Pregnant and Angry”



Stanton Royer, M.D.



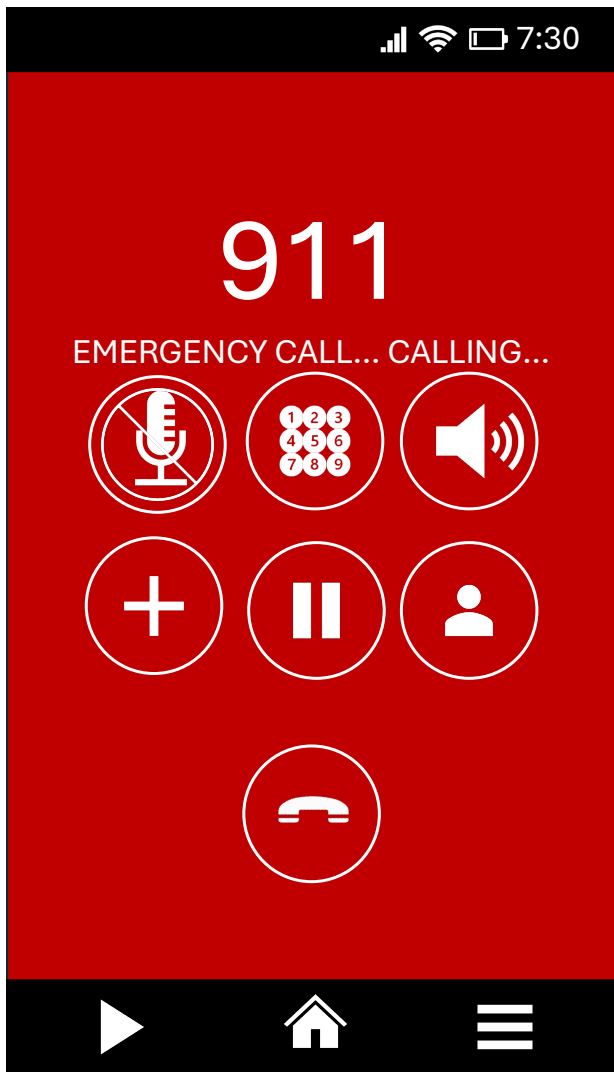Emily Kiernan, D.O.



Rocket City Emergency
MEDICAL CONFERENCE



EMORY
UNIVERSITY



EMS Dispatch

**ALS ambulance is dispatched E-3 to
“30-year-old female: fall down
stairs”**



Enroute



Rocket City Emergency
MEDICAL CONFERENCE

**Updated to
“Patient is 37 weeks pregnant”**



On Scene

RR	HR	BP	SpO ₂
14	104	160/110	94%

Obviously gravid 30yo female

Lying at bottom of stairs

(12+ steps)

Eyes are open, staring off

Sweat pants are wet



On Scene

Per husband (who is very upset): Heard loud noise and found her at bottom of carpeted stairs

She seemed groggy and agitated when found

Has not been feeling well last few days; C/o HA



On Scene

PMHx: Pregnant at 37 weeks EGA

History of Meth use prior to pregnancy

Husband reports she has abstained during pregnancy

No problems during pregnancy (but no PNC)

Medications: Prenatal Vitamins



Enroute

RR	HR	BP	SpO ₂
18	114	140/98	99%

Becomes more alert, but is markedly confused and agitated...

Becomes combative

“Should we go straight to L&D or stop in the ED?”

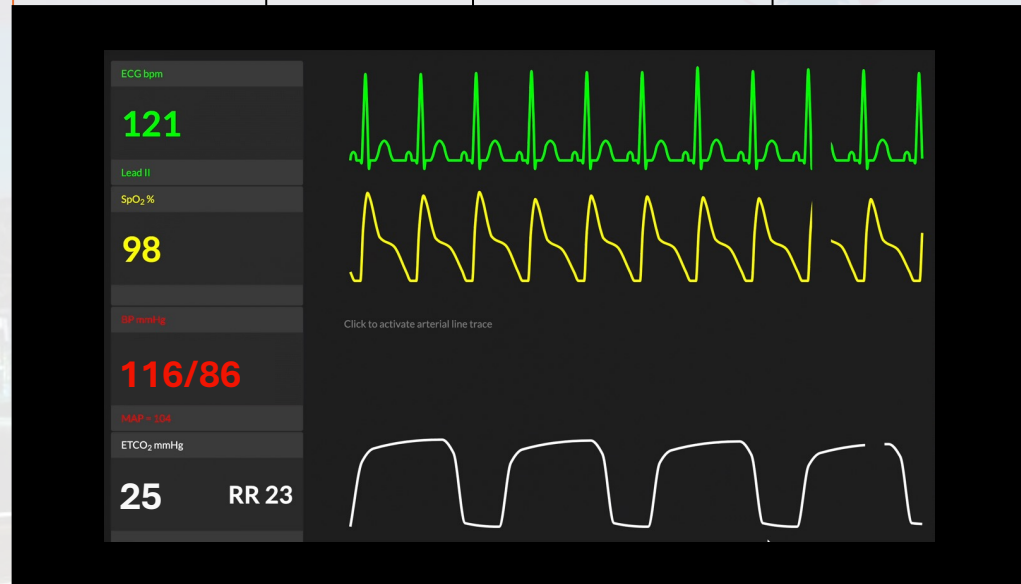
FSBG

150mg%

EMS Report

M
I
S
T

RR	HR	BP	SpO ₂
22	118	120/80	99%





ED Arrival

RR	HR	BP	SpO ₂	Temp
16	119	85/54	94%	37.1C



https://commons.wikimedia.org/wiki/File:Maternity_Grants_For_Pregnant_Women.jpg

ED Arrival

RR	HR	BP	SpO ₂	Temp
16	119	85/54	94%	37.1C

Hypertension → hypotension

Increasing tachycardia / hypoxia

Reevaluation?





<https://www.flickr.com/photos/alvericemoon/>

ED Arrival

More alert, now c/o HA and abdominal pain

Palpable fundus at epigastrium

Gross blood noted when taking underwear off



YH, Zhang YS, Chen JY, et al. *ol.* 2023;228(5):535-546. doi: 10.1016/j.ajog.2022.10.014Am J Obstet Gynec

<https://www.flickr.com/photos/alvericemoon/>

ED Arrival

A = intact

B = b/l BS | sats 94% RA

C = **hypotensive | tachycardic**

D = alert | **altered**

E = trauma naked | **vaginal bleeding |**

no additional trauma



Rocket City Emergency
MEDICAL CONFERENCE



<https://www.flickr.com/photos/alvericemoon/>

Recap

37 week pregnant

HTN + HA

Trauma + AMS

Vaginal bleeding +
Hypotension



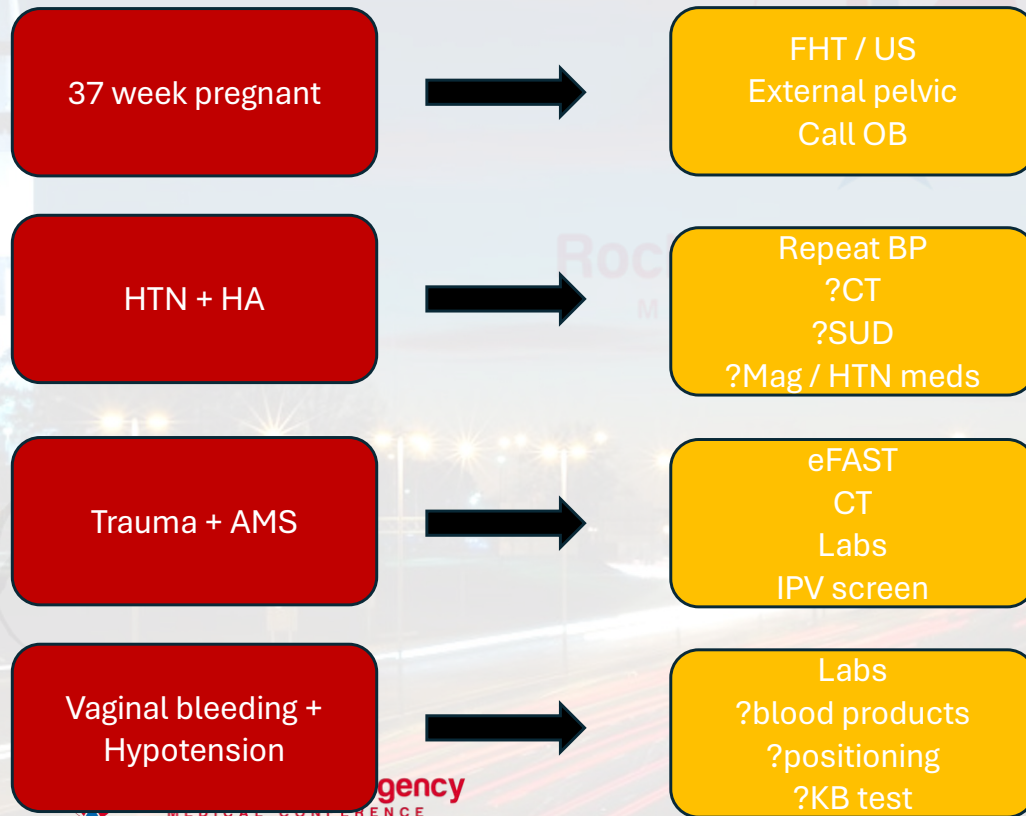
Rocket City Emergency
MEDICAL CONFERENCE

gency

MEDICAL CONFERENCE



What do you do next?





<https://www.flickr.com/photos/alvericemoon/>

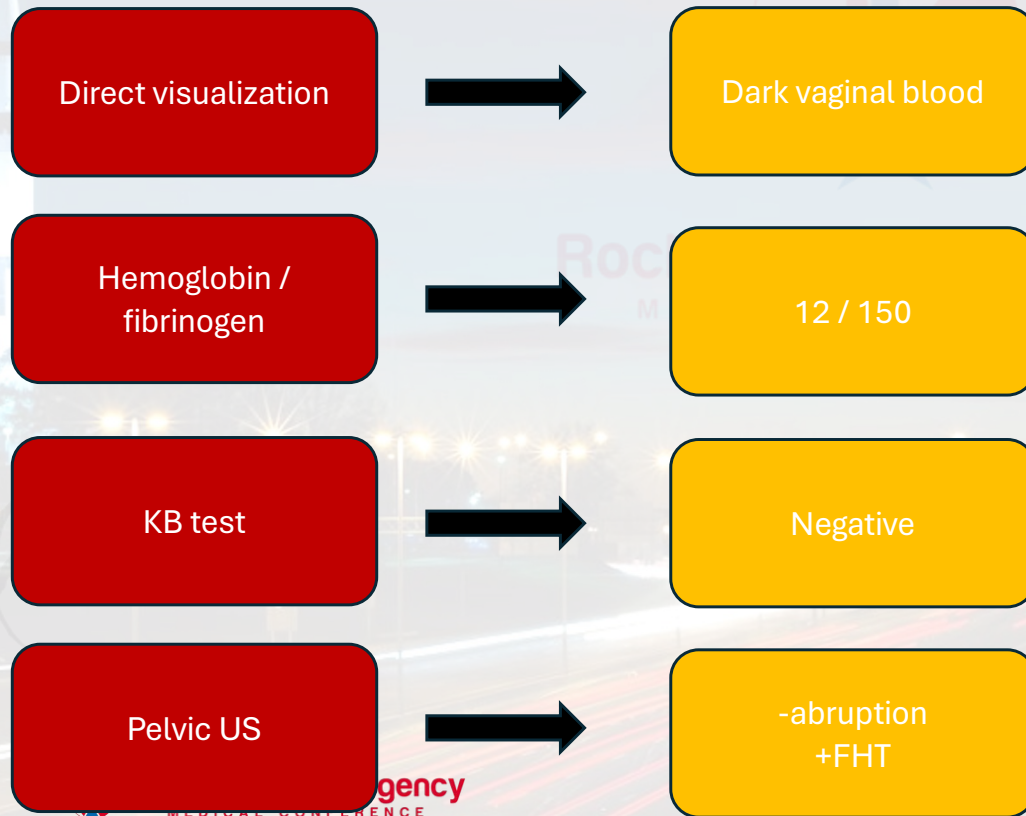
Making the diagnosis..

- ? Visualization of blood on pelvic examination
- ? Initial labs: hemoglobin, fibrinogen, coags
- ? Kleihauer-Betke test
- ? Ultrasound



<https://www.flickr.com/photos/alvericemoon/>

What do you do next?




Emergency
MEDICAL CONFERENCE



<https://www.flickr.com/photos/alvericemoon/>

Making the diagnosis..



Know clinical test limitations

Make a clinical diagnosis



Emory University SOM Photo

Resolution

RR	HR	BP	SpO ₂	Temp
22	119	96/44	95%	37.1c

Rocket City Emergency
MEDICAL CONFERENCE

What is the diagnosis?



Steve Wood UAB Photo


Resolution

RR	HR	BP	SpO ₂	Temp
22	119	96/44	95%	37.1c

Eclamptic seizure with a traumatic placental abruption

Dispo: OR with OB for emergent c-section

Panel Discussion and Q&A



**COMING
IN 2026!**

Thank you!



Altogether



Rocket City Emergency
MEDICAL CONFERENCE



COMING
IN 2026!

*A major case
of the*

BLUES

Rocket City Emergency Medicine Conference